

Equine Thermography Case Study

Unusual Behaviour

15.2 hh eight-year-old Cob

This horse has been with his present owner for five years, and has experienced no previous problems, but recently started bucking when asked to canter, better to the right, worse to the left.

Pre- and post-exercise scans were taken (about 120 images) at an ambient temperature of 10°C.

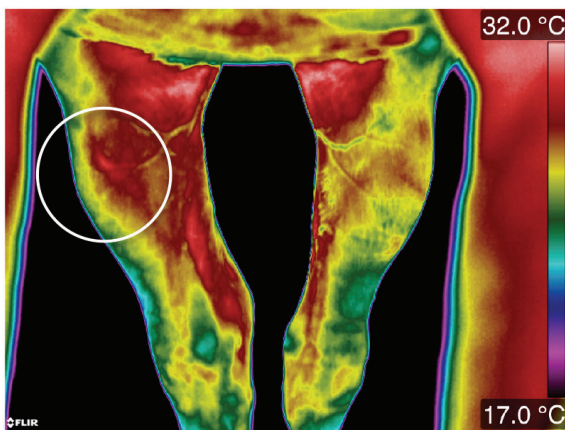


Figure 1. Proximal hindlimbs cranial view

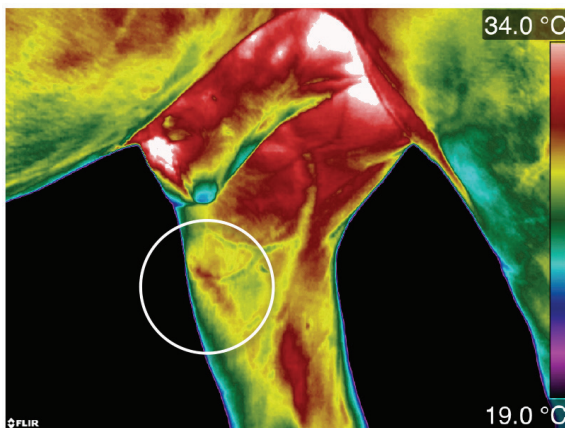


Figure 2. Right stifle medial view

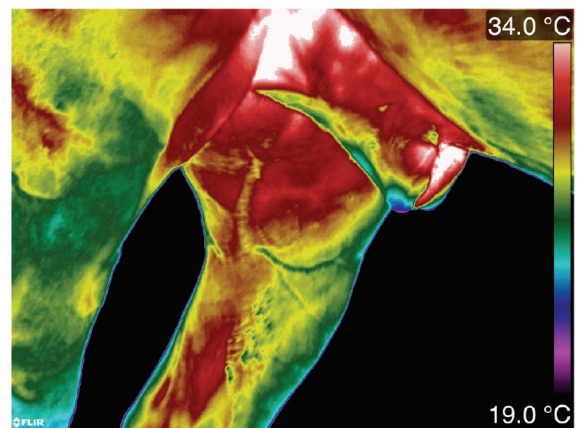


Figure 3. Left stifle medial view

Taking all the images into consideration, looking at symmetry and analysing pre- and post-exercise images, it was possible to see that this horse had an asymmetric abnormal thermal pattern in the proximal right hindlimb, cranial and medial views (circled white) and by analysing the solar views it could be seen that the horse was not placing so much weight on the right hind limb as he was on the left hind limb, adding to the evidence that it was this region that required further investigation by a vet.

The owner's vet investigated the region with ultrasound and diagnosed a small tear in a stifle ligament. The horse had the injury treated and three months post operation was cantering on both left and right reins with no problems.

Article author:
Elaine Hall – Equine Thermography

